



Effect of Pollen Extract on the Development of Experimental Atherosclerosis in Rabbits

J. Wójcicki¹, L. Samochowiec¹, B. Bartłomowicz¹, A. Hinek², M. Jaworska¹ and B. Gawrońska-Szklarz¹

¹Institute of Pharmacology and Toxicology and ²Department of Histology and Embryology, Medical Academy, Szczecin (Poland)

(Received 11 March, 1986)

(Revised received 29 May, 1986)

(Accepted 31 May, 1986)

Summary

Our previous studies have shown that the pollen extract, Cernitin, reveals lipid-lowering properties in animals and humans. The present study was designed to investigate the influence of Cernitin on the development of experimental atherosclerosis in rabbits over a period of 12 weeks.

Forty male mongrel rabbits were divided into 4 equal groups: (1) controls, (2) animals receiving high-fat diet (HFD) containing cholesterol and coconut oil, (3) HFD + pollen extract, and (4) HFD + clofibrate.

The most pronounced reduction in lipid metabolism and in the severity of plaque formation occurred after the pollen extract had been applied. The total cholesterol content in serum and liver homogenate was depressed by 67% and 45%, respectively, while the serum HDL cholesterol and α -lipoproteins level was increased by 19% and from 7.73% to 21.73% respectively. The cytochrome P-450 content in the liver microsomes was elevated by 98% (nmol/ g liver). Atherosclerotic plaque intensity at 12 weeks, measured planimetrically, averaged 85.5% in HFD-fed animals vs 33.7% in pollen extract-treated rabbits. These findings suggest that Cernitin, in addition to significantly lowering serum lipid levels in rabbits on an experimental diet, may modify lipid disposition in major arteries.

Key words: *Experimental atherosclerosis – High-fat diet fed rabbits – Pollen extract*

Introduction

We previously reported that pollen extract shows a remarkable lipid-lowering effect in animals fed high-fat diet [1,2] and in humans [3,4]. These studies have however, not taken into consideration the possible beneficial effect of the agent on atherosclerosis development.

Pollen extracts – Cernitin T60 and Cernitin GBX (AB Cernelle, Vegeholm, Sweden) are taken from 6 plant species: Rye grass, Maize, Timothy grass, Pine, Alder flower, and Orchard grass. After removing the membrane with a solvent, the content of the pollen grains are flushed out through the hila. The solvent is then removed and the extract is microbiologically digested. During degradation, high-molecular weight material, that

may be difficult to absorb, is reduced to low-molecular weight substances that can be easily absorbed in the gastrointestinal tract. Thus, extract from the pollens are free from antigens and other high-molecular weight substances. Cernitin T60 contains water-soluble (6.0-9.2% of α -amino acids) while Cernitin GBX comprises mainly fat-soluble (10-16% of phytosterols) substances.

The chemical composition of pollen has been subjected to several investigations [5-7]. Numerous chemical substances have been identified and isolated from pollen: 21 amino-acids (including 10 essential aminoacids), all known vitamins, enzymes, coenzymes, sterols, minerals and trace elements. As much as 23%

TABLE 1

LEVEL OF TOTAL LIPIDS (TL), TOTAL CHOLESTEROL (Ch), HDL CHOLESTEROL (HDL-Ch), TRIGLYCERIDE (TG), PHOSPHOLIPIDS (P), β -LIPOPROTEINS (β -L) AND FREE FATTY ACIDS (FFA) IN THE BLOOD SERUM OF RABBITS
Values are means \pm SE.

Group	TL (g/l)	Ch (mmol/l)	HDL-Ch (mmol/l)	TG (mmol/l)	P (mmol/l)	β -L (g/l)	FFA (μ mol/l)
1	3.74 \pm 0.29	2.60 \pm 0.23	0.99 \pm 0.10	0.98 \pm 0.09	0.36 \pm 0.01	1.13 \pm 0.30	251.93 \pm 25.71
2	25.40 \pm 2.90	32.60 \pm 4.48	0.69 \pm 0.07	1.06 \pm 0.06	0.79 \pm 0.09	12.25 \pm 2.70	359.22 \pm 40.92
3	10.69 \pm 2.52	10.63 \pm 3.79	0.82 \pm 0.08	0.79 \pm 0.08	0.57 \pm 0.11	8.35 \pm 2.44	150.44 \pm 22.74
4	21.76 \pm 1.07	19.50 \pm 1.60	0.91 \pm 0.14	1.02 \pm 0.14	0.78 \pm 0.07	13.56 \pm 1.14	171.01 \pm 26.41
<i>P</i>							
1/2	< 0.001	< 0.001	< 0.05	> 0.7	< 0.001	< 0.001	< 0.05
2/3	< 0.01	< 0.01	> 0.2	> 0.05	> 0.1	> 0.3	< 0.001
2/4	> 0.2	> 0.1	> 0.5	> 0.8	> 0.8	> 0.9	< 0.01
3/4	< 0.001	< 0.05	> 0.4	> 0.1	> 0.1	> 0.05	> 0.4

of the fatty acids contained in Cernitin GBX is in the form of linolenic acid.

The objective of the present study was to determine the effect of induced hyperlipidemia and atherosclerotic lesions in rabbits. The rabbit was chosen because of its susceptibility to atherosclerosis and its similarity to man in bile acid metabolism.

Materials and methods

Animals and diets

The study was carried out on 40 male mongrel rabbits with initial body weight 3.0-3.8 kg fed with a standard basic diet, randomly divided into 4 equal groups: group 1 – was control, group 2 – received a high-fat diet (HFD), group 3 was given a HFD and pollen extracts (Cernitin T60 – 50 mg/kg/24 h + Cernitin GBX – 10 mg/kg/24 h) orally, group 4 was administered a HFD and clofibrate (Pharmaceutical Works 'Polfa' 25 mg/kg/ 24 h) orally. The HFD consisted of (g/kg/24 h) cholesterol (0.5), hydrogenated coconut oil (1.0), cholic acid (0.1). Pollen extracts and clofibrate were mixed with the diet and given every morning as a pellet to non-fed rabbits.

The experiment lasted 12 weeks. Animals were weighed every 2 weeks. At the end they were deprived of food for 18 h and then killed. Blood samples were taken for biochemical measurements by heart puncture and aorta and liver were excised.

Biomechanical methods

In blood serum the following lipid fractions were assayed: total lipid level [8], triglycerides [9], total cholesterol [10] and cholesterol of HDL fraction [11]. Serum samples were also analyzed for phospholipids [12], β -lipoproteins [13] and free fatty acids [14]. Lipoproteins were separated into fractions by electrophoresis on agarose gel [15].

Total lipids, triglyceride and total cholesterol [8-10] were determined in liver homogenate.

Microsomal cytochrome P-450 concentration was estimated [16] and microsomal total cholesterol content was measured [17]. Protein content of microsomes was also analyzed [18].

Anatomopathological evaluation

The aorta was opened longitudinally from the aortic valve to the iliac arteries and examined grossly for the extent of atherosclerosis. The percentage of surface of intima covered by atherosclerotic plaques was evaluated planimetrically.

Sections from the aorta were taken, fixed in 10% buffered formalin and embedded in paraffin. They were then stained with hematoxylin and eosin, Sudan black and orcein for microscopic examination.

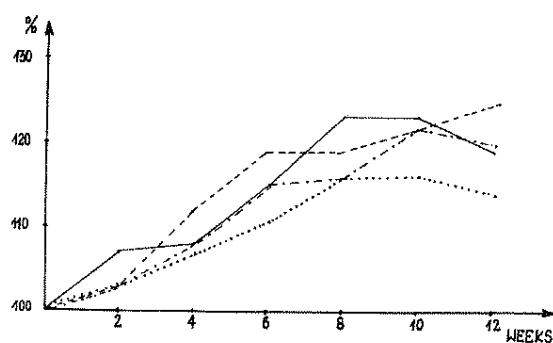


Fig. 1. Body weight of rabbits in the course of experiment expressed in percentage. Initial body weight is taken as 100%. — control group; - - - - HFD; - · - · - HFD + pollen extract; · · · · · HFD + clofibrate.

TABLE 2
SEPARATION OF LIPOPROTEINS INTO FRACTIONS

Values are means \pm SE.

Group	Lipoproteins (%)	
	α	pre- β + β
1	57.33 \pm 3.10	42.67 \pm 3.10
2	7.73 \pm 1.26	92.27 \pm 1.26
3	21.73 \pm 6.22	78.27 \pm 6.22
4	5.21 \pm 0.76	94.79 \pm 0.76
<i>P</i>		
1/2	< 0.001	< 0.001
2/3	< 0.05	< 0.05
2/4	> 0.1	> 0.05
3/4	< 0.02	< 0.02

Statistical analysis

The data were analysed by Duncan's test [19].

Results

Body weight of animals

Body weight of rabbits increased and after 12 weeks it was 14-25% higher than the initial values (Fig. 1).

Biochemical studies

In the blood serum of rabbits fed with HFD, the total lipid content was elevated by 579%, total cholesterol by 1154%, phospholipids by 119%, β -lipoproteins by 984% and free fatty acids by 43% (Table 1). HDL cholesterol was decreased significantly by 30%, while the level of triglyceride was practically unchanged. In the group treated with Cernitin, the elevation of serum total lipids,

cholesterol and free fatty acids was markedly and significantly suppressed.

HDL cholesterol content in this group of animals was increased in comparison with group 2, while the level of phospholipids and β -lipoproteins was insignificantly diminished. In rabbits on HFD, clofibrate administration did not significantly influence the serum lipid content except for free fatty acids.

Only two fractions were separated by lipoprotein electrophoresis: pre- β - and β -fractions remained inseparable (Table 2). The percentage content of α -lipoproteins in rabbits of group 2 was reduced, from 57.33% in control animals to 7.73% , but in rabbits treated with pollen extract it was significantly elevated to 21.73%, as compared with rabbits on HFD.

In the liver homogenate of animals receiving HFD the level of all investigated lipid fractions significantly increased: total lipids by 41%, triglyceride by 88%, and total cholesterol by 146%; total cholesterol in liver microsomes was higher by 77% (Table 3). The content of lipids in liver homogenate of rabbits given HFD and Cernitin or clofibrate was depressed but the change did not reach the control level. Total cholesterol concentration was significantly depressed, both in homogenate and in microsomes under the influence of pollen extract, in comparison with group 2.

The cytochrome P-450 content in the liver microsomes was slightly raised in rabbits receiving the HFD. Animals treated with Cernitin and ingesting simultaneously the HFD, exhibited

TABLE 3
CONTENT OF TL AND TG IN LIVER HOMOGENATE AND Cc IN LIVER HOMOGENATE AND LIVER MICROSOMES (mg/g wet tissue)

Values are means \pm SE.

Group	TL	TG	Cc	
			in homogenate	in microsomes
1	87.30 \pm 9.76	16.50 \pm 1.52	7.03 \pm 1.33	0.22 \pm 0.02
2	123.30 \pm 10.90	31.10 \pm 1.59	17.29 \pm 1.27	0.39 \pm 0.07
3	107.03 \pm 19.82	15.14 \pm 2.28	9.49 \pm 0.99	0.23 \pm 0.03
4	62.90 \pm 6.22	11.46 \pm 2.28	13.67 \pm 1.33	0.30 \pm 0.06
<i>P</i>				
1/2	< 0.05	< 0.001	< 0.001	< 0.05
2/3	> 0.4	< 0.001	< 0.001	< 0.05
2/4	< 0.01	< 0.001	> 0.05	> 0.1
3/4	> 0.1	> 0.1	< 0.05	> 0.1

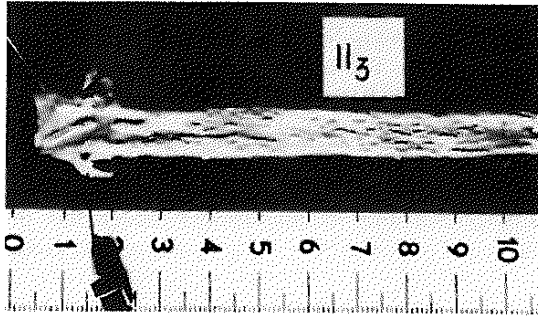


Fig. 2. Macroscopic picture of the aortic internal surface of a rabbit treated with a high-fat diet. The atherosclerotic plaques cover almost the whole surface of intima.

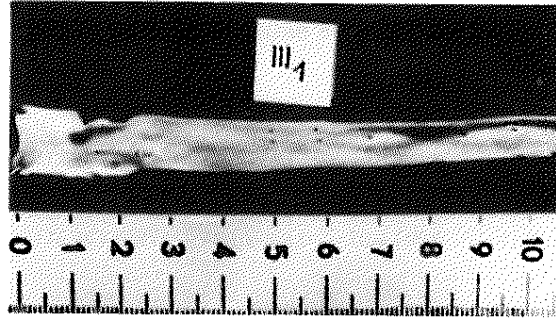


Fig. 3. Macroscopic picture of the aortic intima of a rabbit receiving the pollen extract. Significant inhibition of the formation of atheroma occurs.

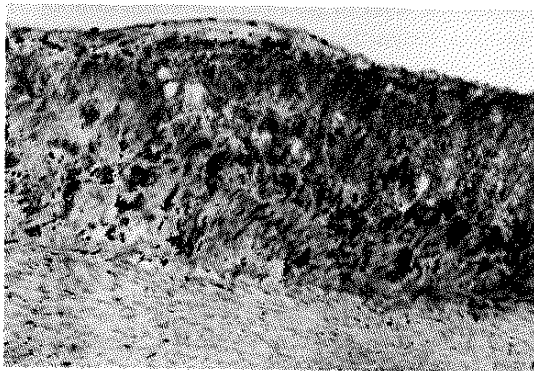


Fig. 4. Micrograph of aorta of a rabbit on a high-fat diet. Well developed atherosclerotic plaque with numerous foam cells and lipid droplet appears. Sudan black + hematoxylin and eosin, $\times 160$.

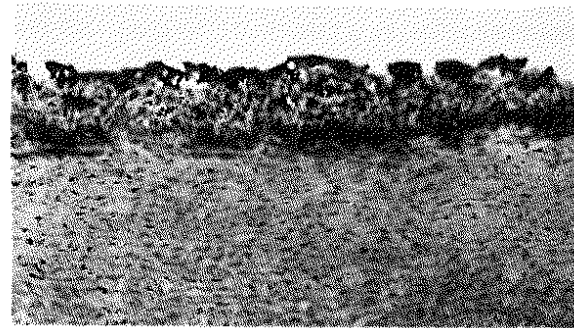


Fig. 5. Histological picture of aorta of a rabbit given pollen extract. Atherosclerotic plaque is thinner and less developed than in group 2. Sudan black + hematoxylin and eosin, $\times 160$.

TABLE 4
CONTENT OF CYTOCHROM P-450 IN LIVER

Group ^a	Mean \pm SE		
	nmol/1 mg protein	nmol/1 g liver	nmol/total liver
1	1.13 \pm 0.10	5.22 \pm 0.97	599.06 \pm 116.85
2	1.34 \pm 0.11	6.76 \pm 0.43	850.86 \pm 61.92
3	2.06 \pm 0.13	13.39 \pm 1.22	1601.05 \pm 473.91
4	1.60 \pm 0.09	8.17 \pm 0.33	1433.71 \pm 161.12
<i>P</i>			
1/2	> 0.2	< 0.01	> 0.1
2/3	< 0.01	< 0.01	> 0.1
2/4	> 0.1	< 0.05	< 0.05
3/4	< 0.05	< 0.05	> 0.7

^a Four animals in each group.

an average cytochrome P-450 content markedly more than that of controls and group 2 as well as rabbits on clofibrate (Table 4).

Anatomopathological findings

Gross alterations

The intima of the aorta of rabbits of group 1 (controls) was unchanged (Table 5). In animals given the HFD, marked development of atherosclerotic plaques had occurred, the plaque coverage averaging 83.5% (Fig. 2), compared to only 33.7% in the pollen extract-treated animals (Fig 3). There was increase in the weight of livers of rabbits of group 2 and group 4, but it was unchanged in animals receiving pollen extract (Table 5).

TABLE 5
PERCENTAGE OF SURFACE OF THE AORTIC INTIMA COVERED BY ATHEROSCLEROTIC PLAQUES AND MEAN LIVER WEIGHT EXPRESSED IN g/1000 g BODY WEIGHT

Values are means \pm SE.

Group	Atherosclerotic plaques	Liver weight
1	0	29.94 \pm 1.37
2	83.5 \pm 1.55	34.07 \pm 1.49
3	33.7 \pm 10.65	29.49 \pm 2.01
4	58.1 \pm 5.91	33.25 \pm 1.76
<i>P</i>		
1/2	–	< 0.001
2/3	< 0.001	> 0.1
2/4	< 0.001	> 0.6
3/4	> 0.05	> 0.1

Microscopic studies

The aorta of rabbits of group 2 contained numerous atherosclerotic lesions of various intensity (Fig 4). Most large lesions causing the wall to protrude into the lumen on the long segment of the vessel, transgressed the limit of the elastic intima. Numerous foam cells loaded with lipids, fibroblasts and single smooth muscle cells in the lesions appeared. Lipid infiltrations consisting of small droplets, appeared also in myocytes in the media.

We also observed clearly focal proliferation of myocytes present in the media. Atherosclerotic plaques contained myocytes and numerous

collagen fibres and less numerous elastic fibers. In rabbits receiving pollen extract less severe histological alterations were observed (Fig. 5). The plaques were thinner and contained less foam cells, than in animals of group 2. No essential inhibition of the formation of atheroma occurred in the aorta of the HFD-fed rabbits given clofibrate.

Discussion

The reports on the serum lipid-lowering effect orally administered pollen extracts to rats [2,20] could be confirmed in the rabbits fed a high-fat diet. Moreover, an apparently less severe atheromata in the aorta of rabbits given pollen extract, than in the high-fat diet animals, alone and in combination with clofibrate, was related to the decreased serum concentration of cholesterol and other lipid fractions.

Our previous studies considered the metabolic activity of Cernitin extracts – T60 and GBX administered separately and in combination [20]. The combination resulted in synergistic and intensified effects on the metabolic processes. We have shown in this experiment the elevated content of cytochrome P-450 in the liver microsomes. Cytochrome P-450 dependent 7 α -hydroxylase is involved in the metabolism of cholesterol [21]. Thus, administration of pollen extract to rabbits may be responsible for stimulation of the liver microsomal 7 α -hydroxylation of cholesterol to bile acids. Earlier it was demonstrated, that pollen extract is able to diminish platelet aggregation in vitro as well as in vivo [3,4]. The platelets of the arterial blood have been depicted as significant factors in early atherogenesis as well as in late thrombotic complications of advanced atherosclerosis.

Previous studies have revealed that anti-inflammatory agents markedly suppress the development of atherosclerotic plaque formation in cholesterol-fed rabbits [22]. Decreased atherosclerotic plaque formation could result from a reduced rate of cholesterol influx and an increased rate of efflux from rabbit aorta. The definite anti-inflammatory action of Cernitin extracts was revealed in the case of croton oil-induced edema [23]. In the cotton pellet test in

rats pollen extract showed an anti-inflammatory activity corresponding to the inflammation-inhibiting effect of phenylbutazone, but was completely devoid of toxicity.

The mechanism of antiatherosclerotic action of pollen extract may be due to its known constituents, such as polyunsaturated fatty acids and sterols interfering with intestinal absorption of cholesterol [24].

Linoleic acid has antithrombotic effects in animals and man [25]. Moreover, replacement of dietary saturated fatty acids by linoleic acid lowers the risk for myocardial (re)infarction [26] as well as cardiovascular death rate [27]. The cholesterol-lowering effect of linoleic acid is probably due to that fraction which is converted to linolenic acid or some further metabolite [28]. Recently it has been demonstrated that timnodonic acid when administered to rats is able to cause a doubling of the vascular production of prostacyclin-like material [29]. Our conclusions favor the polifactorial basis of the effect of pollen extract on the high-fat diet-induced atherosclerosis in rabbits.

References

1. Samochowiec, L. and Wojcicki, J., Effect of pollen on serum and liver lipids in rats fed on a high-lipid diet, *Herba Polon.*, 27 (1981) 333.
2. Samochowiec, L. and Wojcicki, J., Influence of Cernitin extracts on serum and liver lipids in rats fed on a high-fat diet, *Herba Polon.*, 29 (1983) 165.
3. Wojcicki, J., Kosmider, K., Samochowiec, L. and Woyke, M., Clinical evaluation of Cernilton as lipid-lowering agent, *Herba Polon.*, 29 (1983) 56.
4. Kosmider, K., Wojcicki, J., Samochowiec, L., Woyke, M. and Gornik, W. Effect of Cernilton on platelet aggregation in vivo, *Herba Polon.*, 29 (1983) 237.
5. Kvanta, E., Sterols in pollen, *Acta Chem. Scand.*, 22 (1968) 1261.
6. Nielson, N., Gromer, J. and Lunden, R., Investigations on the chemical composition of pollen from some plants, *Acta Chem. Scand.*, 9 (1957) 1672.
7. Nielson, N. and Holmstrom, B., On the occurrence of folic acid, folic acid conjugation and folic acid conjugases in pollen, *Acta Chem. Scand.*, 11 (1957) 101.
8. Zollner, N. and Kirsch, K., Uber die quantitative Bestimmung von lipoiden (Mikromethode) mittels

- der vielen naturlichen Lipoiden (allen bekannten Plasmolipoiden) gemeinsamen Sulfophospho-Vanillen-Reaktion, *Z. Ges. Exp. Med.*, 135 (1962) 545.
9. Eggstein, M. and Kreuz, F.H., Eine neue Bestimmung der Neutralfette in Blutserum und Gewebe, *Klin. Wschr.*, 44 (1966) 262.
10. Blaszczyzn, M., Precise and simple determination of total cholesterol in serum (in Polish), *Wiad. Lek.*, 16 (1970) 1413.
11. Burstein, H. and Samaille, J., Sur un dosage rapide du cholesterol lie aux a- e aux B-lipoproteine s du serum, *Clin. Chim. Acta*, 5 (1960) 609.
12. King, E.J. and Wootton, I.D.F., *Microanalysis in Medical Biochemistry*, Churchill Ltd., London 1956, p.25.
13. Kellen, J. and Belay, J., Beobachtungen bei der turbidimetrischen Bestimmung der B-lipoproteine in Serum with Amylpectin, *Klin. Wschr.*, 41 (1963) 200.
14. Duncombe, W.G., The colorimetric micro-determination of nonesterified fatty acids in plasma, *Clin. Chim. Acta*, 9 (1964) 122.
15. Gros, M., Electrophoretic separation of pre-stained serum lipoproteins on cellulose acetate, agarose gel and polyacrylamide, *Clin. Chim. Acta*, 45 (1973) 165.
16. Omura, T. and Sato, R., The carbon monoxide-binding pigment of liver microsomes, Part 2 (Solubilization, purification and properties), *J. Biol. Chem.*, 239 (1964) 2379.
17. Rudel, L.L. and Morris, M.D., Determination of cholesterol using O-phthalaldehyde, *J. Lipid. Res.*, 14 (1973) 364.
18. Lowry, O., Rosebrough, N.J., Farr, A.L. and Randal, R.J., Protein measurement with Folin phenol reagent, *J. Biol. Chem.*, 193 (1951) 265.
19. Duncan, D.B., Multiple range and multiple F tests, *Biometrics*, 11 (1955) 1.
20. Wojcicki, J. and Samochowiec, L., Further studies on Cernitins: Screening of the hypolipidemic activity in rats, *Herba Polon.*, 30 (1984) 115.
21. Myant, M.B. and Mitropoulos, K.A., Cholesterol 7 α -hydroxylase, *J. Lipid Res.*, 18 (1979) 135.
22. Bailey, J.M., Watson, R., Bombard, R.W. and Randazzo, R., Anti-inflammatory drugs in experimental atherosclerosis, Part 5 (Influence of cortisone acetate on short-term and long-term cholesterol fluxes in atherosclerotic aorta). *Atherosclerosis*, 51 (1984) 299.
23. Itoh, R., Pharmacological studies on Cernilton, Cernitin GBX and Cernitin T60, *J. Med. Soc. Toho Univ.*, 15 (1968) 1.
24. Yeshurin, D. and Gotto, Jr. A.M., Drug treatment of hyperlipidemia, *Amer. J. Med.*, 60 (1976) 379.
25. Renaud, S. and Gautherson, P., Dietary fats and experimental (cardiac and venous) thrombosis. *Hemostasis*, 74 (1973) 253.
26. Dayton, S., Pearce, M.L., Hashimoto, S. and Dixon, W.J., A controlled trial of a diet high in unsaturated

- fat in preventing complications of atherosclerosis, *Circulation*, 40 (Suppl. II) (1969) 1.
27. Turpeinen, O, Effect of cholesterol-lowering diet on mortality from coronary heart disease and other causes, *Circulation*, 59 (1979) 1.
28. Horrobin, D.F. and Mankuns, M.S., How do polyunsaturated fatty acids lower plasma cholesterol levels? *Lipids*, 18 (1983) 558.
29. Hornstra, G., Prostanoids and their precursor fatty acids in the management of arterial thrombosis, *Progr. Pharmacol.*, 4 (1982) 75.